

# ACOG COMMITTEE OPINION

Number 822

(Replaces Committee Opinion No. 770, March 2017)

## Committee on Gynecologic Practice

*The American Urogynecologic Society endorses this document. This Committee Opinion was developed by the American College of Obstetricians and Gynecologists' Committee on Gynecologic Practice.*

**INTERIM UPDATE:** This Committee Opinion is updated as highlighted to include the U.S. Food and Drug Administration's 2020 recommendation that laparoscopic power morcellation for myomectomy or hysterectomy be performed only with a tissue containment system as well as more recent data on the use of containment systems and preoperative use of magnetic resonance imaging.

## Uterine Morcellation for Presumed Leiomyomas

**ABSTRACT:** Morcellation is a surgical technique used to reduce the size of the uterus or myomas by creating smaller pieces to allow the tissue to be removed through small incisions or with laparoscopic instruments. Open (uncontained) morcellation of the uterus and myomas has been scrutinized because of the possible spread of an unsuspected leiomyosarcoma while using a power morcellator during a hysterectomy or myomectomy for presumed symptomatic uterine leiomyomas. Before considering morcellation of the uterus, a woman should be evaluated to determine if she is at increased risk of malignancy of the uterine corpus. Morcellation of a malignancy is contraindicated and women should be evaluated preoperatively to identify malignancy. However, leiomyosarcoma cannot be reliably diagnosed preoperatively; thus, there is a risk that a woman with a presumed leiomyoma may have a malignancy that may be spread through morcellation, leading to a potentially worsened prognosis. Although an abdominal hysterectomy or myomectomy may reduce the chance of spreading cancer cells in women with undiagnosed leiomyosarcoma, it is associated with increased morbidity when compared with minimally invasive approaches. The obstetrician–gynecologist and patient should engage in shared decision making, including informed consent, explaining the risks and benefits of each approach to surgery for presumed leiomyomas, the risks and benefits of morcellation, and alternatives to morcellation.

## Recommendations and Conclusions

The American College of Obstetricians and Gynecologists makes the following recommendations and conclusions regarding uterine morcellation (manual or power):

- Before considering morcellation of the uterus, a woman should be evaluated to determine if she is at increased risk of malignancy of the uterine corpus.
- Preoperative evaluation includes risk stratification and the appropriate use of imaging, cervical cancer screening, and endometrial tissue sampling to identify malignancy; although, leiomyosarcoma is not reliably identifiable preoperatively.
- The patient should be informed of the possible risk of disseminating an occult uterine malignancy by open morcellation, as well as the risk of disseminating benign uterine tissue.
- Although an abdominal hysterectomy or myomectomy may reduce the chance of spreading cancer cells in women with undiagnosed leiomyosarcoma, it is associated with increased morbidity when compared with minimally invasive approaches. These factors must be weighed against the risk of encountering a leiomyosarcoma at the time of surgery for presumed leiomyomas (also called fibroids), as well as the associated morbidity and potential mortality associated with that diagnosis.
- Based on the 2017 Agency for Healthcare Research and Quality (AHRQ) report, which used the largest and most comprehensive dataset and rigorous analytic methods to determine estimates of prevalence of leiomyosarcoma, patients may be informed that the risk of unexpected leiomyosarcoma may range from 1 in 770 surgeries to less than 1 in 10,000 surgeries for presumed symptomatic leiomyomas.

- The obstetrician–gynecologist and patient should engage in shared decision making, including informed consent, explaining the risks and benefits of each approach to surgery for presumed leiomyomas, the risks and benefits of morcellation, and alternatives to morcellation.

## Background

Morcellation is a surgical technique used to reduce the size of the uterus or myomas by creating smaller pieces to allow the tissue to be removed through small incisions or with laparoscopic instruments. Gynecologists have performed manual morcellation to remove an enlarged uterus through the vagina or a small abdominal incision for decades (1, 2). Other procedures to reduce uterine size include myomectomy, bivalving, wedge resection, or coring. Morcellation also has been performed on smaller uteri during the performance of supracervical hysterectomies. Introduced in 1993, electromechanical devices, commonly referred to as power morcellators, shave or cut tissue to allow tissue extraction (3).

Open (uncontained) morcellation of the uterus and myomas has been scrutinized because of the possible spread of an unsuspected leiomyosarcoma while using a power morcellator during a hysterectomy or myomectomy for presumed symptomatic uterine leiomyomas. In response, the U.S. Food and Drug Administration (FDA) issued a Safety Communication in November 2014 warning “against the use of laparoscopic power morcellators in the majority of women undergoing myomectomy or hysterectomy for treatment of fibroids” (4). After that warning, use of laparoscopic hysterectomy and myomectomy decreased (5–8). During the same time frame, non-blood transfusion complications and 30-day readmissions increased (5). Furthermore, with the decreased use of minimally invasive approaches and increased use of abdominal procedures, the incidence of major and minor surgical complications related to hysterectomy significantly increased after the 2014 FDA warning (8). Although the FDA expressed specific concerns about power morcellation, it is important to recognize that all morcellation techniques for hysterectomy or myomectomy have the potential to spread unsuspected cancer cells in the pelvis and abdomen (9–11). In February 2020, the FDA released an updated Safety Communication recommending that laparoscopic power morcellation for myomectomy or hysterectomy be performed only with a tissue containment system that is legally marketed in the United States for use during laparoscopic power morcellation and is compatible with only specifically designated laparoscopic power morcellators (12). Additionally, the FDA’s February 2020 guidance stated that laparoscopic power morcellators for the removal of uterine tissue containing suspected leiomyomas should not be used in patients who are postmenopausal or older than 50 years, or “candidates for removal of tissue (en bloc) through the vagina or via a mini-laparotomy incision.” The FDA guidance applies

only to presumed uterine leiomyomas and does not advise against the use of power morcellation for surgical management of other diagnoses. In December 2020, the FDA released an updated Safety Communication reaffirming that laparoscopic power morcellation for myomectomy or hysterectomy only be performed with a tissue containment system and only in appropriately selected patients; additional recommendations for clinicians included to conduct a thorough preoperative screening and to engage in shared decision making, discussing the risks and benefits of all relevant treatment options, with patients (13).

The primary focus of this document is to address surgery being performed for presumed symptomatic leiomyomas. Furthermore, the term “morcellation” in this document refers to open or uncontained morcellation; that is, morcellation that is performed in the peritoneal cavity without first placing the specimen into a containment bag. Although briefly addressed in a subsequent section, this document is not focused on surgery performed for other indications, such as hysterectomy performed to correct pelvic organ prolapse. Furthermore, this document is not applicable to care for patients undergoing hysteroscopic surgery (myomectomy or morcellation, or both).

## Epidemiology

Although uterine leiomyomas are common, leiomyosarcoma is rare, with an estimated incidence of 0.36 per 100,000 woman–years (14). The median age at diagnosis of leiomyosarcoma is 54 years, with an interquartile range of 48–63 years (15). History of tamoxifen use for more than 5 years is associated with increased risk of endometrial carcinoma and also may increase the risk of leiomyosarcoma (16–18). A history of pelvic irradiation and certain hereditary cancer syndromes, such as hereditary retinoblastoma syndrome and Li Fraumeni syndrome, also are associated with an increased risk of leiomyosarcoma (19–23). Research has shown that uterine size and rapid uterine growth are not associated with increased risk of leiomyosarcoma (17).

## Preoperative Evaluation

Before considering morcellation of the uterus, a woman should be evaluated to determine if she is at increased risk of malignancy of the uterine corpus. Preoperative evaluation includes risk stratification and the appropriate use of imaging, cervical cancer screening, and endometrial tissue sampling to identify malignancy; although leiomyosarcoma is not reliably identifiable preoperatively. Imaging findings suspicious for malignancy should preclude morcellation. Cervical cancer screening should be conducted according to current cervical screening guidelines, (24–26) and abnormal results should be evaluated properly. Women with abnormal uterine bleeding also should be evaluated appropriately (27, 28).

No test can accurately rule out the diagnosis of leiomyosarcoma preoperatively. The diagnosis usually is not made until pathologic evaluation of the uterus or leiomyoma is performed. Although endometrial biopsy or dilation and curettage may diagnose leiomyosarcoma, these are not reliable diagnostic tests for leiomyosarcoma (17). Dynamic magnetic resonance imaging (MRI) and lactate dehydrogenase isoenzyme testing have been suggested as diagnostic methods for leiomyosarcoma in the preoperative evaluation; however, the evidence for these methods is weak and based on limited clinical studies (29). A retrospective cohort study of 1,960 women (18–87 years) evaluated five MRI features of leiomyosarcoma to screen for this diagnosis preoperatively in women planning myomectomy and prospectively identified patients with leiomyosarcoma with 100% sensitivity. However, the positive predictive value of MRI at detecting leiomyosarcoma was notably low (14%), related to low prevalence of this disease (30). More data on the potential efficacy of preoperative evaluation with MRI are needed. Furthermore, there are no data supporting biopsy of presumed leiomyomas. Considering the potential for large or multiple leiomyomas, and because biopsy would involve an invasive procedure with its associated risks, direct biopsy of leiomyomas is not practical.

### The Risk of Unsuspected Leiomyosarcoma in Women With Presumed Leiomyomas

There is no consensus regarding the absolute risk of a presumed leiomyomatous uterus harboring a leiomyo-

sarcoma. A summary of the studies contributing to the estimated prevalence is provided in Table 1. The 2014 quantitative assessment released by the FDA reviewed published and unpublished literature on patients undergoing surgery between 1980 and 2011 to estimate the prevalence of unsuspected uterine sarcoma and leiomyosarcoma in women undergoing hysterectomy or myomectomy for presumed leiomyomas (31). The final analysis evaluated a total of nine studies (eight publications and one abstract) that included 9,160 women, of whom only 5.5% were from prospective studies. Only studies in which a leiomyosarcoma was identified were included, and studies of women undergoing surgery for presumed leiomyomas in which no leiomyosarcoma was found were excluded from the analysis. Based on this review, the FDA calculated that prevalence was 1 in 352 for unsuspected uterine sarcoma and 1 in 498 for unsuspected leiomyosarcoma in women undergoing hysterectomy or myomectomy for presumed benign leiomyomas (31). Because studies in which no leiomyosarcoma was identified were excluded, the estimated prevalence provided in this report is likely inflated. This analysis was included in the FDA's Safety Communication boxed warning on power morcellation issued in November 2014, stating that "...uterine tissue may contain unsuspected cancer. The use of laparoscopic power morcellators during fibroid surgery may spread cancer and decrease the long-term survival of patients. This information should be shared with patients when considering surgery with the use of these devices" (4). The November 2014 FDA Safety Communication also

**Table 1.** Summary of the Estimated Prevalence of Leiomyosarcoma at the Time of Surgery for Presumed Leiomyomas

Publication	Number of Studies Included	Number of Women Included in the Analysis	Estimated Prevalence of Leiomyosarcoma
FDA 2014*	9	9,160	1/498
FDA 2017†	20	90,910	1/750 to 1/570
Pritts 2015‡	133 (meta-analysis)	30,193	1/1,961
Bojahr 2015§	1 (single institution)	10,731	1/4,360
Agency for Healthcare Research and Quality 2017	160 (meta-analysis)	136,195	<1/10,000 to 1/770

\*U.S. Food and Drug Administration. Quantitative assessment of the prevalence of unsuspected uterine sarcoma in women undergoing treatment of uterine fibroids [archived]. Silver Spring (MD): FDA; 2014. Available at: <https://www.fda.gov/downloads/MedicalDevices/Safety/AlertsandNotices/UCM393589.pdf>. Retrieved November 5, 2018.

†U.S. Food and Drug Administration. FDA updated assessment of the use of laparoscopic power morcellators to treat uterine fibroids. Silver Spring (MD): FDA; 2017. Available at: <https://www.fda.gov/downloads/MedicalDevices/ProductsandMedicalProcedures/SurgeryandLifeSupport/UCM584539.pdf>. Retrieved November 5, 2018.

‡Pritts EA, Vanness DJ, Berek JS, Parker W, Feinberg R, Feinberg J, et al. The prevalence of occult leiomyosarcoma at surgery for presumed uterine fibroids: a meta-analysis. *Gynecol Surg* 2015;12:165–77.

§Bojahr B, De Wilde RL, Tchatchian G. Malignancy rate of 10,731 uteri morcellated during laparoscopic supracervical hysterectomy (LASH). *Arch Gynecol Obstet* 2015;292:665–72.

||Hartmann KE, Fonnesebeck C, Surawicz T, Krishnaswami S, Andrews JC, Wilson JE, et al. Management of uterine fibroids. Comparative Effectiveness Review No. 195. AHRQ Publication No. 17(18)-EHC028-EF. Rockville (MD): Agency for Healthcare Research and Quality; 2017. Available at: [https://effectivehealthcare.ahrq.gov/sites/default/files/pdf/cer-195-uterine-fibroids-final\\_0.pdf](https://effectivehealthcare.ahrq.gov/sites/default/files/pdf/cer-195-uterine-fibroids-final_0.pdf). Retrieved November 6, 2018.

stated that “laparoscopic power morcellators are contraindicated for removal of uterine tissue containing suspected fibroids in patients who are peri- or postmenopausal, or are candidates for en bloc tissue removal” (4).

In 2017, the FDA released an updated assessment of the use of laparoscopic power morcellators for treatment of leiomyomas (32). This analysis included a review of English-language publications released between April 2014 and April 2017 to update the 2014 analysis. A total of 23 studies were included in this analysis, and 20 studies (totaling 90,910 women) contributed to the estimated prevalence of leiomyosarcoma at the time of surgery for presumed leiomyomas. Depending on the modeling methodology used, the estimated prevalence of uterine sarcoma was 1 in 305 to 1 in 360 women, and for leiomyosarcoma the estimated prevalence was 1 in 570 to 1 in 750 women. These estimates were consistent with the previous FDA analysis, and the organization continued to caution against the use of laparoscopic power morcellators in most women undergoing hysterectomy or myomectomy for presumed leiomyomas (32).

Other published data demonstrate a much lower prevalence of leiomyosarcoma identified at the time of surgery for presumed leiomyomas. A 2015 meta-analysis of 133 studies determined that the overall prevalence of leiomyosarcoma among women having surgery for presumed leiomyomas was 1 in 1,961 (0.051%; 95% credible interval, 0.16–0.98) (33). In this same meta-analysis, when considering only the 64 prospective studies, the prevalence was approximately 1 in 8,300 (0.012%; 95% credible interval, 0.01–0.75) surgeries for presumed leiomyomas (33). A single-institution series, also published in 2015, found two instances of occult leiomyosarcoma in 8,720 women having surgery for presumed leiomyomas (1 in 4,360 or 0.023%) (34).

In 2017, AHRQ published a systematic review of the existing literature and a meta-analysis addressing the prevalence of leiomyosarcoma in presumed leiomyomas (35). The AHRQ report included data from 160 studies and 136,195 women; 29% of the data were from women included in prospective studies. According to the AHRQ meta-analysis, the overall risk of identifying a leiomyosarcoma after surgery for presumed leiomyomas was 0.02% (range: 0.05–0.09%) in prospective studies, and 0.08% (range: 0.05–0.13%) in retrospective studies (35). Translating this data to risk per number of surgeries, an unexpected leiomyosarcoma would be found in fewer than 1–13 of every 10,000 surgeries performed for symptomatic leiomyomas (1/10,000 to 1/770) (35).

### **The Effects of Morcellation on the Prognosis of Patients With Leiomyosarcoma**

Leiomyosarcomas are aggressive malignancies that spread rapidly through intraperitoneal and hematogenous pathways. For example, a study using 1998–2013

data from the National Cancer Database reported that, even when confined to the uterus (stage I), the 5-year survival rate is 55.4% (15). Evidence that morcellation of a leiomyosarcoma worsens a patient’s prognosis is limited. Small retrospective studies have reported an increase in recurrence of leiomyosarcoma among patients who had undergone morcellation (10, 11, 36–38) and upstaging in women who had inadvertent morcellation of a leiomyosarcoma and subsequently underwent surgical re-exploration and staging (10, 39). These findings are not consistent across all studies, and definitive conclusions are difficult to establish because of the heterogeneity of the studies, retrospective design, the small number of patients included, and bias related to referral patterns (9).

The 2017 AHRQ meta-analysis provided additional information regarding prognosis. This report included 28 studies totaling 715 women with leiomyosarcoma at the time of the initial surgery and of these, 24 studies (384 women) contributed data regarding the effect of the morcellation method (35). Based on the methods used in this meta-analysis, estimates of survival were presented as ranges with Bayesian credible intervals (BCI). (Although BCIs and confidence intervals represent similar concepts, they are based on a different set of statistical assumptions and, thus, calculated differently.) Using this approach, survival varied by morcellation technique. Based on modeling, the expected 5-year survival was 30% for women undergoing power morcellation (95% BCI, 13–61%), 59% for scalpel morcellation (95% BCI, 33–84%), and 60% for women in whom no morcellation was used (95% BCI, 24–98%) (35). Although the survival estimate for power morcellation was lower than that of scalpel morcellation or no morcellation, the BCIs for the three groups overlap, making the uncertainty of the estimates very large, especially at longer follow-up times. The 2017 AHRQ meta-analysis acknowledges that significant gaps in the evidence exist and more data are needed (35).

### **Alternatives and Other Approaches to Morcellation**

For women undergoing hysterectomy for benign disease, the American College of Obstetricians and Gynecologists recommends a minimally invasive approach whenever feasible (40). If the uterus is too large to be removed intact through the vagina, morcellation is required to complete a vaginal hysterectomy. The alternative to morcellation is to remove the uterus intact through an abdominal incision (abdominal hysterectomy). Similarly, removal of uterine myomas at the time of myomectomy without morcellation necessitates an abdominal incision.

In addition to using an abdominal approach to hysterectomy, other alternative techniques to avoid the risks of power morcellation have been proposed, including hand-assisted morcellation through a mini-laparotomy and vaginal manual morcellation (19, 41, 42).



Morcellation in a containment bag also has been suggested as a method to avoid intraperitoneal spread of morcellated tissue, and a number of containment systems have been developed to facilitate tissue extraction after morcellation (19, 43). However, several studies in the setting of power or scalpel morcellation have demonstrated that containment bags may perforate or leak (44–46). In February 2020, the FDA recommended performing laparoscopic power morcellation for myomectomy or hysterectomy only with a tissue containment system, legally marketed in the United States for use during laparoscopic power morcellation, which in turn must be used with a compatible power morcellator (12). This new guidance is reportedly based on bench and animal testing. Although the American College of Obstetricians and Gynecologists acknowledges the FDA's new recommendation, more information is needed. It is still unknown whether the use of a containment system prevents the spread of benign or malignant tissue. In addition to concern that the bags may leak (44, 47), bags may make morcellation more cumbersome, resulting in increased operative time (48, 49, 50). The potential for obstructed visualization of other abdominal contents, resulting in injury to those obscured organs, is another theoretical concern. Further development and evaluation of methods to eliminate the spread of tissue and cancer into the peritoneal cavity are needed.

### **Risks Associated With Laparoscopic Versus Abdominal Approaches to Hysterectomy or Myomectomy**

In addition to the potential spread of unsuspected malignancy, when comparing a laparoscopic approach with an abdominal approach for a hysterectomy or myomectomy, it is important to consider morbidity related to the procedure itself. Abdominal hysterectomy is associated with the following adverse outcomes: infection, hemorrhage, venous thromboembolic complications, nerve injury, genitourinary injury, and gastrointestinal injury (51). Abdominal hysterectomy is associated with higher rates of many of these complications compared with laparoscopic-assisted vaginal hysterectomy and laparoscopic hysterectomy (Table 2) (52). Compared with abdominal hysterectomy, laparoscopic approaches to hysterectomy are associated with more rapid recovery, fewer febrile episodes, and reduced risk of wound or abdominal wall infection (53). Additionally, compared with abdominal hysterectomy, laparoscopic hysterectomy is associated with a lower risk of venous thromboembolism, transfusion, and bowel perforation, as well as a lower mortality risk (52). Abdominal myomectomy is associated with similar risks. A 2014 systematic review (nine studies including 808 eligible women) reported that laparoscopic myomectomy was associated with less postoperative pain, less postoperative fever, and shorter hospital stay than abdominal myomectomy (54). The authors noted

that additional studies are needed to assess differences in other postoperative outcomes among surgical approaches to myomectomy.

Although an abdominal hysterectomy or myomectomy may reduce the chance of spreading cancer cells in women with undiagnosed leiomyosarcoma, it is associated with increased morbidity when compared with minimally invasive approaches. These factors must be weighed against the risk of encountering a leiomyosarcoma at the time of surgery for presumed leiomyomas, as well as the associated morbidity and potential mortality associated with that diagnosis. Because of the rarity of leiomyosarcoma and the wide range of reported prevalence of leiomyosarcoma diagnosed after surgery for presumed leiomyomas, quantifying the risks and benefits of different surgical approaches, especially for purposes of patient counseling, is difficult. For example, it may be difficult for a woman to place the risk of leiomyosarcoma in perspective when counseled that the risk may range from 1 in 498 surgeries to fewer than 1 in 10,000 procedures.

To help clarify comparison of outcomes, several modeling studies have been published on abdominal versus laparoscopic approach to hysterectomy, incorporating procedure-related risks and the risks associated with morcellation of unsuspected malignancy. One study used a simulation model to compare three methods of hysterectomy (abdominal, laparoscopic without morcellation, and laparoscopic with power morcellation). The model incorporated an overall malignancy (all types) risk estimate of 0.27% (1 in 370) (55). In the model, this risk was varied in the age-stratified analysis, based on the knowledge that the prevalence of leiomyosarcoma was greater with increasing age. This study demonstrated that laparoscopy with morcellation was associated with poorer quality of life and reduced overall life-years compared with laparoscopy without morcellation. However, both laparoscopic techniques (with morcellation and without morcellation) were associated with better outcomes when compared with abdominal hysterectomy (55). When stratified by age, the model showed that for women younger than 40 years, the cancer-associated deaths in the laparoscopic morcellation group (0.94 per 10,000 women) were balanced by the fewer deaths attributed to abdominal hysterectomy (0.97 per 10,000 fewer deaths for laparoscopic versus abdominal hysterectomy). However, with advancing age, the model predicted that mortality in the laparoscopy with morcellation arm exceeded that in the abdominal hysterectomy arm, with 18 additional deaths per 10,000 women in those 60 years and older (55).

A shared clinical decision tool was applied to a theoretical cohort of 20,000 women with leiomyomas undergoing hysterectomy; 10,000 underwent laparoscopic hysterectomies and 10,000 had abdominal hysterectomies (Table 3) (56). Abdominal hysterectomy was associated with increased surgically related morbidities,

**Table 2.** Risk of Major Morbidities and Mortality Associated With Abdominal or Laparoscopic Hysterectomy

Outcome	Abdominal Hysterectomy	Laparoscopic Hysterectomy	OR (95 % CI) (Laparoscopic Compared With Abdominal Hysterectomy)	P value
DVT	2,879 (0.74%)	502 (0.66 %)	0.88 (0.80–0.96)	0.04
PE	3,099 (0.8%)	522 (0.68 %)	0.85 (0.77–0.93)	0.006
DVT or PE	3,281 (0.84 %)	529 (0.69 %)	0.48 (0.24–0.95)	0.0004
Blood transfusion	18,124 (4.7 %)	1,805 (2.4 %)	0.56 (0.42–0.74)	0.0001
Bowel perforation	490 (0.13 %)	52 (0.07)	N/A	0.0001
Bladder injury	17 (<0.01 %)	0 (0 %)	0.29 (0.27–0.31)	N/A
Acute MI	133 (0.03 %)	13 (0.02 %)	0.58 (0.55–0.61)	0.2
Length of stay >6 days	15,917 (4.1 %)	804 (1.1 %)	0.29 (0.27–0.31)	0.0001
Death	123 (0.03 %)	9 (0.01 %)	0.69 (0.39–1.2)	0.036

Abbreviations: CI, confidence interval; DVT, deep vein thrombosis; OR, odds ratio; PE, pulmonary embolism; MI, myocardial infarction; N/A, not available.

Reprinted from Wiser A, Holcroft CA, Tulandi T, Abenham HA. Abdominal versus laparoscopic hysterectomies for benign diseases: evaluation of morbidity and mortality among 465,798 cases. *Gynecol Surg* 2013;10:117–22.

longer hospital stay, and decreased patient satisfaction compared with laparoscopic hysterectomy with morcellation (including risk of leiomyosarcoma). However, lap-

aroscopic hysterectomy with morcellation was associated with shorter median time to recurrence, shorter recurrence-free survival, and lower overall survival.

**Table 3.** Comparison of Outcomes of Abdominal Hysterectomy Without Morcellation With Laparoscopic Hysterectomy With Morcellation

Outcome	Estimated Net Difference*
Venous thromboembolism	+2%
Small bowel obstruction	+2.8%
Adhesions	+18.2% (transverse incision)
Surgical site infection	+4.8%
Length of hospital stay	+2 days
Return to work	+13.6 days
Postoperative pain	+48%
Patient satisfaction	-50.4 points <sup>†</sup>
Estimated blood loss	+45 cc
Uterine sarcomas morcellated	-0.28%
Local recurrence	-47.8%
Median time to recurrence	+28.8 months
5-year recurrence-free survival	+25%
Overall survival at 5 years	+27%

\*Positive values indicate a higher estimate with abdominal hysterectomy compared with laparoscopic hysterectomy.

<sup>†</sup>Quality-of-life score (ranging from 0 to 100 points) using a standardized instrument (SF-36). Higher scores denote a higher quality of life.

Data from Hur HC, King LP, Klebanoff MJ, Hur C, Ricciotti HA. Fibroid morcellation: a shared clinical decision tool for mode of hysterectomy. *Eur J Obstet Gynecol Reprod Biol* 2015;195:122–7.

Two studies using decision-tree models, first published in 2015 and updated in 2017 to include data from studies on the prevalence of sarcoma published after the November 2014 FDA Safety Communication, compared outcomes of abdominal hysterectomy with laparoscopic hysterectomy (57, 58). Notably, in the sensitivity analyses included in these modeling studies, the results are highly dependent on the variation of the reported prevalence of leiomyosarcoma in women undergoing surgery for presumed leiomyomas. In the 2015 study, the comparison of cancer-associated mortality and procedure-related mortality was dependent on the estimated leiomyosarcoma prevalence used in the model, with comparison favoring a laparoscopic approach when lower estimates were used, and an abdominal approach when higher estimates were used. If the estimated incidence of leiomyosarcoma was 0.0015% (1 in 667 or 15 per 10,000 surgeries), mortality between the two groups was equivalent (57).

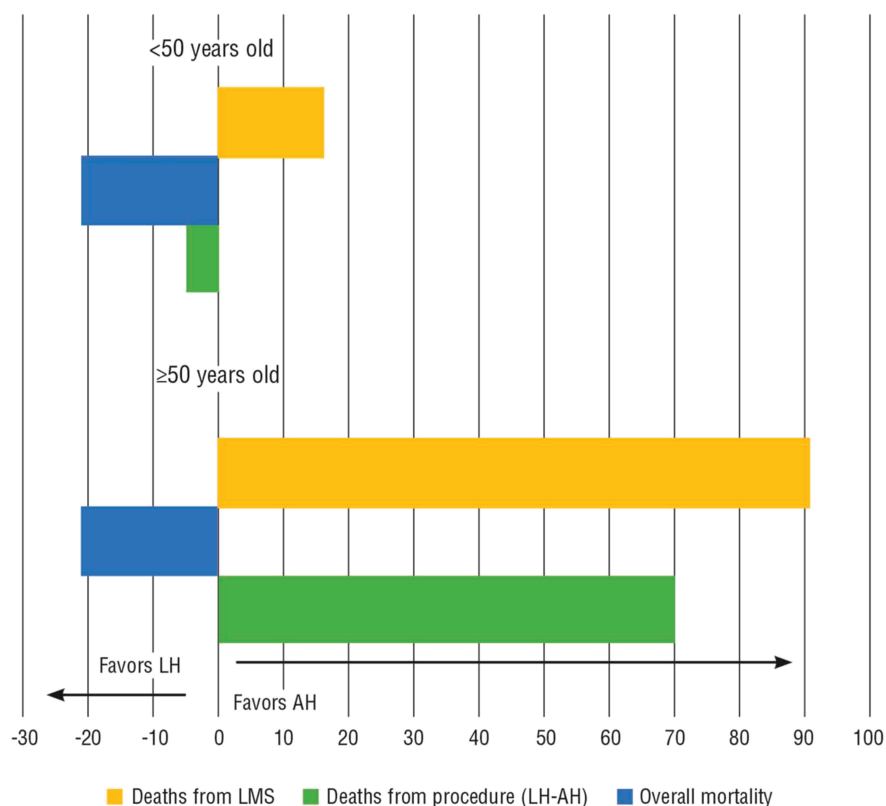
In the 2017 updated analysis, a weighted average from newer published studies was used to estimate the incidence of leiomyosarcoma (0.0017%, or 1 in 558 procedures) (58). Using this estimate for leiomyosarcoma and estimates of mortality due to the surgical procedures, overall mortality was similar between the abdominal and laparoscopic hysterectomy groups, although in sensitivity analyses, most scenarios in the analysis favored the laparoscopic hysterectomy group. This decision analysis also was conducted separately for different age groups, using the age-group specific prevalence of leiomyosarcoma (58). For purposes of analysis, the data were dichotomized according to age: younger than 50 years, and 50 years and older. In women younger than 50 years, mortality considerations favored the laparoscopic hysterectomy with power morcellation group. There were 16 more deaths in the laparoscopic hysterectomy group due to leiomyosarcoma, but 21 fewer deaths attributed to the laparoscopic (as opposed to abdominal) approach. However, for women aged 50 years and older, the results differed; there were 91 more deaths in the laparoscopic hysterectomy group due to leiomyosarcoma and 70 fewer deaths attributed to the laparoscopic (as opposed to abdominal) approach (58). The authors concluded that overall mortality was not significantly different between the laparoscopic and the abdominal approaches to hysterectomy when considering higher death rates due to morcellation of a leiomyosarcoma with laparoscopic hysterectomy compared with the higher procedure-related mortality with abdominal hysterectomy. With variation in the rates of leiomyosarcoma prevalence, most scenarios favored a laparoscopic approach. The 2017 analysis also identified the importance of age as a risk factor, concluding that the risk of death associated with morcellation was significantly greater in women 50 years of age and older (58) (Fig. 1).

Although the modeling and decision-tree analyses provide helpful information by incorporating procedural risks and risks related to morcellation of unsuspected

leiomyosarcoma and interpreting these risks for patient counseling, there are variations in the results depending on prevalence estimates used in these models. In general, it appears that for younger women (particularly for those younger than 50 years based on decision models), a laparoscopic approach for hysterectomy or myomectomy, with power morcellation if indicated, is a reasonable option when balancing the procedure-related risks with those associated with an unsuspected leiomyosarcoma. However, for older women (50 years and older based on decision models), although the overall risk of an unsuspected leiomyosarcoma and procedure-related mortality is low, incremental mortality is greater in those women undergoing a laparoscopic approach with power morcellation because of the higher risk of an unsuspected leiomyosarcoma as women age. Accordingly, the FDA's February 2020 guidance stated that laparoscopic power morcellators for the removal of uterine tissue containing suspected leiomyomas should not be used in patients who are postmenopausal or older than 50 years (12). Importantly, in these modeling and decision-tree analyses, the estimated prevalence of leiomyosarcoma used in the models generally exceed the estimated prevalence identified in the 2017 AHRQ meta-analysis (35). Although the estimated prevalence of leiomyosarcoma reported in the AHRQ report has not been applied to similar models, it is reasonable to assume that cancer-associated mortality would be lower than reported in older models.

## Other Risks of Morcellation

Most of the published literature on morcellation subsequent to the publication of the November 2014 FDA Safety Communication is about the risks of inadvertently morcellating a uterine leiomyosarcoma during surgery for presumed leiomyomas. However, morcellation also may be useful for removing a small uterus, such as at the time of laparoscopic-assisted supracervical hysterectomy (LASH procedure), or when hysterectomy is performed as a component of pelvic organ prolapse repair. Endometrial carcinoma also has been identified in morcellation specimens. A retrospective review of 10,731 laparoscopic supracervical hysterectomies performed with the assistance of a power morcellator identified eight cases (0.07%, or 1 in 1,429 procedures) of endometrial carcinoma (34). In this study, with an average of 65.58 months of follow-up, no endometrial carcinomas had recurred. Other series have reported frequencies of 0.2–0.4% (1 in 250 to 1 in 502 procedures) of endometrial carcinomas identified in cases in which power morcellation was performed during surgery for benign indications (59–61). Abnormal uterine bleeding or postmenopausal bleeding is the most common presenting symptom in women with endometrial adenocarcinoma, and women should undergo appropriate preoperative evaluation to exclude coexisting endometrial malignancy.



**Figure 1.** Number of Incremental Deaths Per 100,000 in Laparoscopic Hysterectomy and Abdominal Hysterectomy, Stratified by Age. Abbreviations: AH, abdominal hysterectomy; LH, laparoscopic hysterectomy; LMS, leiomyosarcoma. Reprinted from Siedhoff MT, Doll KM, Clarke-Pearson DL, Rutstein SE. Laparoscopic hysterectomy with morcellation vs abdominal hysterectomy for presumed fibroids: an updated decision analysis following the 2014 Food and Drug Administration safety communications. *Am J Obstet Gynecol* 2017;216:259.e1–6.

Another consequence of morcellation is the potential spread of benign tissue through the pelvis and peritoneal cavity. A 2016 systematic review reported that laparoscopic hysterectomy or myomectomy with nonconfined morcellation was associated with sequelae, including intraperitoneal implants of endometriosis (1.4%), adenomyosis (0.57%), parasitic leiomyomas (0.9%) and, rarely, disseminated peritoneal leiomyomatosis (62). Although these benign conditions are of lesser consequence when compared with malignancy, additional medical or surgical interventions may be required for treatment of disseminated benign tissue.

### Nonpower Morcellation and Morcellation of Tissue at the Time of Vaginal Extraction

Concerns about morcellation primarily have focused on the use of power morcellation or morcellation within the abdominal cavity. Scalpel morcellation of an enlarged uterus also may be used to assist with the extraction of the uterus at the time of vaginal hysterectomy or with the extraction of an enlarged uterus from the vagina at the time of total laparoscopic hysterectomy. Morcellation in these circumstances, in theory, also may result in the spread of undetected malignant cells. However, data regarding this risk and its effect on survival are extremely limited. It has been suggested that if morcellation is

necessary for tissue extraction through the vagina at the time of laparoscopic hysterectomy, the uterus could be placed in a specimen bag before vaginal extraction (19).

### Shared Decision Making

Patients and clinicians should use shared decision making to facilitate making choices regarding use of morcellation in gynecologic surgery for presumed leiomyomas. Proper informed consent must be obtained. Women must be informed of the risks and benefits of any medical intervention and alternative treatment options (63). This also applies to consideration of morcellation. The patient should be informed of the possible risk of disseminating an occult uterine malignancy by open morcellation, as well as the risk of disseminating benign uterine tissue. Current evidence suggests that the risk of a leiomyosarcoma is rare, but estimates of prevalence are wide-ranging, making it challenging for patients to understand the magnitude of the risk. However, based on the 2017 AHRQ report, which used the largest and most comprehensive dataset and rigorous analytic methods to determine estimates of prevalence of leiomyosarcoma, patients may be informed that the risk of unexpected leiomyosarcoma may range from 1 in 770 surgeries to less than 1 in 10,000 surgeries for presumed symptomatic leiomyomas (35). Women also should be informed that the method of leiomyoma removal may affect subsequent morbidity and mortality,



although the prognosis of leiomyosarcoma is poor regardless of the method of removal. The additional risks associated with morcellation and the risks associated with abdominal hysterectomy or other alternatives to morcellation also should be presented.

Discussing the results of modeling studies with women may assist them in interpreting the balance of risks associated with a laparoscopic approach compared with an abdominal approach to hysterectomy or myomectomy for presumed leiomyomas. According to modeling studies that estimated age-stratified risks, the higher risk of leiomyosarcoma in older patients and its effect on the rates of mortality associated with different surgical approaches should be incorporated into patient-centered discussions about surgical options for women with presumed leiomyomas. Although the modeling studies estimate a higher risk of leiomyosarcoma in older women, it is important to note that a postmenopausal woman typically would not undergo hysterectomy or myomectomy for the indication of symptomatic uterine leiomyomas. The mutual sharing of information over time between the clinician and the patient can facilitate the patient's autonomy in the process of making ongoing choices. Ultimately, patient autonomy in the informed consent process must be respected. A list of talking points to consider for counseling women about options is provided in Box 1.

## Conclusion

Uterine morcellation is a surgical technique that is performed to remove a uterus or leiomyomas through small incisions and facilitates minimally invasive surgical approaches. Morcellation may be performed during vaginal, laparoscopic, or abdominal surgery using a scalpel, scissors, or a power morcellator. A commonly used alternative to morcellation of an enlarged uterus is an abdominal hysterectomy. However, compared with minimally invasive approaches, abdominal hysterectomy is associated with higher morbidity and mortality and diminished quality of life.

Morcellation of a malignancy is contraindicated and women should be evaluated preoperatively to identify malignancy. However, leiomyosarcoma cannot be reliably diagnosed preoperatively; thus, there is a risk that a woman with a presumed leiomyoma may have a malignancy that may be spread through morcellation, leading to a potentially worsened prognosis. The risk of unexpected leiomyosarcoma is uncertain, but estimates range from 1 in 498 to less than 1 in 10,000. For women undergoing surgery for presumed leiomyomas, the higher procedural risk of abdominal hysterectomy or myomectomy (to avoid the risk of spreading malignant cells from an unsuspected leiomyosarcoma) must be balanced against the risk of morcellating an unanticipated malignancy and its associated morbidity and mortality. Based on existing data, this balance may favor a minimally invasive approach for younger women. However,

### Box 1. Talking Points to Consider When Counseling Women About Surgery for Presumed Leiomyomas

- The risks and benefits of minimally invasive and abdominal approaches to hysterectomy or myomectomy:
  - Compared with laparoscopic approaches, the abdominal approach for hysterectomy is associated with higher risk of procedure-related morbidity, including venous thromboembolic complications, transfusion, bowel perforation, febrile episodes, and wound infections. It also is associated with increased length of hospital stay, decreased quality of life, and higher mortality.
  - A minimally invasive approach to hysterectomy is advised whenever feasible.
  - Abdominal myomectomy is associated with more postoperative pain, more postoperative fevers, and longer hospital stay than laparoscopic myomectomy.
- The risk of leiomyosarcoma at the time of surgery for presumed leiomyomas increases with age, and estimates are wide-ranging.
- There is a potential risk of spreading malignant cells if morcellation is performed and an unsuspected malignancy is found.
- The overall prognosis of uterine leiomyosarcoma is poor.
- Decisions about surgical approach must balance the risks (morbidity and mortality) associated with the procedure with the risk of morcellating an unsuspected malignancy.
- Decisions about surgical approach should be based on a shared decision-making process between the patient and her obstetrician-gynecologist or other health care professional.

because of the increasing prevalence of leiomyosarcoma with advancing age (and interpreting the age cutoff of 50 years used in the decision analyses as a proxy for menopause), for postmenopausal women, this balance may favor procedures that do not involve morcellation. The obstetrician-gynecologist and patient should engage in shared decision making, including informed consent, explaining the risks and benefits of each approach to surgery for presumed leiomyomas, the risks and benefits of morcellation, and alternatives to morcellation. More research is needed to understand the true prevalence of leiomyosarcoma at the time of surgery for presumed leiomyomas, to better define risk factors for leiomyosarcoma, and to develop preoperative diagnostic tools and methods to improve the safety and efficacy of morcellation.

## References

1. Falcone T, Stovall TG. Hysterectomy. In: Berek JS, editor. *Berek & Novak's gynecology*. 15th ed. Philadelphia (PA): Wolters Kluwer; 2012. p. 803–42.
2. Pratt JH, Gunnlaugsson GH. Vaginal hysterectomy by morcellation. *Mayo Clin Proc* 1970;45:374–87.
3. Steiner RA, Wight E, Tadir Y, Haller U. Electrical cutting device for laparoscopic removal of tissue from the abdominal cavity. *Obstet Gynecol* 1993;81:471–4.
4. U.S. Food and Drug Administration. UPDATED laparoscopic uterine power morcellation in hysterectomy and myomectomy: FDA safety communication [archived]. Silver Spring (MD): FDA; 2014. Available at: <https://wayback.archiveit.org/7993/20170404182209/https://www.fda.gov/MedicalDevices/Safety/AlertsandNotices/ucm424443.htm>. Retrieved November 5, 2018.
5. Harris JA, Swenson CW, Uppal S, Kamdar N, Mahner N, As-Sanie S, et al. Practice patterns and postoperative complications before and after U.S. Food and Drug Administration safety communication on power morcellation. *Am J Obstet Gynecol* 2016;214:98.e1–13.
6. Ottarsdottir H, Cohen SL, Cox M, Vitonis A, Einarsson JI. Trends in mode of hysterectomy after the U.S. Food and Drug Administration power morcellation advisory. *Obstet Gynecol* 2017;129:1014–21.
7. Stentz NC, Cooney LG, Sammel M, Shah DK. Changes in myomectomy practice after the U.S. Food and Drug Administration safety communication on power morcellation. *Obstet Gynecol* 2017;129:1007–13.
8. Multinu F, Casarin J, Hanson KT, Angioni S, Mariani A, Habermann EB, et al. Practice patterns and complications of benign hysterectomy following the FDA statement warning against the use of power morcellation. *JAMA Surg* 2018;153:e180141.
9. Pritts EA, Parker WH, Brown J, Olive DL. Outcome of occult uterine leiomyosarcoma after surgery for presumed uterine fibroids: a systematic review. *J Minim Invasive Gynecol* 2015;22:26–33.
10. Oduyebo T, Rauh-Hain AJ, Meserve EE, Seidman MA, Hinchcliff E, George S, et al. The value of re-exploration in patients with inadvertently morcellated uterine sarcoma. *Gynecol Oncol* 2014;132:360–5.
11. George S, Barysaukas C, Serrano C, Oduyebo T, Rauh-Hain JA, Del Carmen MG, et al. Retrospective cohort study evaluating the impact of intraperitoneal morcellation on outcomes of localized uterine leiomyosarcoma. *Cancer* 2014;120:3154–8.
12. U.S. Food and Drug Administration. UPDATE: The FDA recommends performing contained morcellation in women when laparoscopic power morcellation is appropriate. Silver Spring, MD: FDA; 2020. Available at: <https://www.fda.gov/medical-devices/safety-communications/update-fda-recommends-performing-contained-morcellation-women-when-laparoscopic-power-morcellation>. Retrieved August 7, 2020.
13. U.S. Food and Drug Administration. Update: perform only contained morcellation when laparoscopic power morcellation is appropriate. FDA Safety Communication. Silver Spring, MD: FDA; 2020. Available at: <https://www.fda.gov/medical-devices/safety-communications/update-perform-only-contained-morcellation-when-laparoscopic-power-morcellation-appropriate-fda>. Retrieved January 4, 2021.
14. Toro JR, Travis LB, Wu HJ, Zhu K, Fletcher CD, Devesa SS. Incidence patterns of soft tissue sarcomas, regardless of primary site, in the surveillance, epidemiology and end results program, 1978–2001: an analysis of 26,758 cases. *Int J Cancer* 2006;119:2922–30.
15. Seagle BL, Sobecki-Rausch J, Strohl AE, Shilpi A, Grace A, Shahabi S. Prognosis and treatment of uterine leiomyosarcoma: a National Cancer Database study. *Gynecol Oncol* 2017;145:61–70.
16. Lavie O, Barnett-Griness O, Narod SA, Rennert G. The risk of developing uterine sarcoma after tamoxifen use. *Int J Gynecol Cancer* 2008;18:352–6.
17. Ricci S, Stone RL, Fader AN. Uterine leiomyosarcoma: epidemiology, contemporary treatment strategies and the impact of uterine morcellation. *Gynecol Oncol* 2017;145:208–16.
18. Bernstein L, Deapen D, Cerhan JR, Schwartz SM, Liff J, McGann-Maloney E, et al. Tamoxifen therapy for breast cancer and endometrial cancer risk. *J Natl Cancer Inst* 1999;91:1654–62.
19. Siedhoff MT, Cohen SL. Tissue extraction techniques for leiomyomas and uteri during minimally invasive surgery. *Obstet Gynecol* 2017;130:1251–60.
20. Farid M, Ngeow J. Sarcomas associated with genetic cancer predisposition syndromes: a review. *Oncologist* 2016;21:1002–13.
21. Francis JH, Kleinerman RA, Seddon JM, Abramson DH. Increased risk of secondary uterine leiomyosarcoma in hereditary retinoblastoma. *Gynecol Oncol* 2012;124:254–9.
22. Hensley ML, Barrette BA, Baumann K, Gaffney D, Hamilton AL, Kim JW, et al. Gynecologic Cancer InterGroup (GCIg) consensus review: uterine and ovarian leiomyosarcomas. *Int J Gynecol Cancer* 2014;24:S61–6.
23. Skubitz KM, D'Adamo DR. Sarcoma. *Mayo Clin Proc* 2007;82:1409–32.
24. Cervical cancer screening and prevention. Practice Bulletin No. 168. American College of Obstetricians and Gynecologists. *Obstet Gynecol* 2016;128:e111–30.
25. Saslow D, Solomon D, Lawson HW, Killackey M, Kulasingam SL, Cain J, et al. American Cancer Society, American Society for Colposcopy and Cervical Pathology, and American Society for Clinical Pathology screening guidelines for the prevention and early detection of cervical cancer. ACS-ASCCP Cervical Cancer Guideline Committee. *CA Cancer J Clin* 2012;62:147–72.
26. Curry SJ, Krist AH, Owens DK, Barry MJ, Caughey AB, Davidson KW, et al. Screening for cervical cancer: U.S. Preventive Services Task Force Recommendation Statement. U.S. Preventive Services Task Force. *JAMA* 2018;320:674–86.
27. Diagnosis of abnormal uterine bleeding in reproductive-aged women. Practice Bulletin No. 128. American College

- of Obstetricians and Gynecologists. *Obstet Gynecol* 2012; 120:197–206.
28. Kho KA, Lin K, Hechanova M, Richardson DL. Risk of occult uterine sarcoma in women undergoing hysterectomy for benign indications [published erratum appears in *Obstet Gynecol* 2016;127:968]. *Obstet Gynecol* 2016;127:468–73.
29. Goto A, Takeuchi S, Sugimura K, Maruo T. Usefulness of Gd-DTPA contrast-enhanced dynamic MRI and serum determination of LDH and its isozymes in the differential diagnosis of leiomyosarcoma from degenerated leiomyoma of the uterus. *Int J Gynecol Cancer* 2002;12:354–61.
30. Tong A, Kang SK, Huang C, Huang K, Slevin A, Hindman N. MRI screening for uterine leiomyosarcoma. *J Magn Reson Imaging* 2019;49:e282–94.
31. U.S. Food and Drug Administration. Quantitative assessment of the prevalence of unsuspected uterine sarcoma in women undergoing treatment of uterine fibroids [archived]. Silver Spring (MD): FDA; 2014. Available at: <https://www.fda.gov/downloads/MedicalDevices/Safety/AlertsandNotices/UCM393589.pdf>. Retrieved November 5, 2018.
32. U.S. Food and Drug Administration. FDA updated assessment of the use of laparoscopic power morcellators to treat uterine fibroids. Silver Spring (MD): FDA; 2017. Available at: <https://www.fda.gov/downloads/MedicalDevices/ProductsandMedicalProcedures/SurgeryandLifeSupport/UCM584539.pdf>. Retrieved November 5, 2018.
33. Pritts EA, Vanness DJ, Berek JS, Parker W, Feinberg R, Feinberg J, et al. The prevalence of occult leiomyosarcoma at surgery for presumed uterine fibroids: a meta-analysis. *Gynecol Surg* 2015;12:165–77.
34. Bojahr B, De Wilde RL, Tchartchian G. Malignancy rate of 10,731 uteri morcellated during laparoscopic supracervical hysterectomy (LASH). *Arch Gynecol Obstet* 2015;292:665–72.
35. Hartmann KE, Fonnesebeck C, Surawicz T, Krishnaswami S, Andrews JC, Wilson JE, et al. Management of uterine fibroids. Comparative Effectiveness Review No. 195. AHRQ Publication No. 17(18)-EHC028-EF. Rockville (MD): Agency for Healthcare Research and Quality; 2017. Available at: [https://effectivehealthcare.ahrq.gov/sites/default/files/pdf/cer-195-uterine-fibroids-final\\_0.pdf](https://effectivehealthcare.ahrq.gov/sites/default/files/pdf/cer-195-uterine-fibroids-final_0.pdf). Retrieved November 6, 2018.
36. Park JY, Park SK, Kim DY, Kim JH, Kim YM, Kim YT, et al. The impact of tumor morcellation during surgery on the prognosis of patients with apparently early uterine leiomyosarcoma. *Gynecol Oncol* 2011;122:255–9.
37. Bogani G, Cliby WA, Aletti GD. Impact of morcellation on survival outcomes of patients with unexpected uterine leiomyosarcoma: a systematic review and meta-analysis. *Gynecol Oncol* 2015;137:167–72.
38. Raine-Bennett T, Tucker LY, Zaritsky E, Littell RD, Palen T, Neugebauer R, et al. Occult uterine sarcoma and leiomyosarcoma: incidence of and survival associated with morcellation [published erratum appears in *Obstet Gynecol* 2016;127:405]. *Obstet Gynecol* 2016;127:29–39.
39. Einstein MH, Barakat RR, Chi DS, Sonoda Y, Alektiar KM, Hensley ML, et al. Management of uterine malignancy found incidentally after supracervical hysterectomy or uterine morcellation for presumed benign disease. *Int J Gynecol Cancer* 2008;18:1065–70.
40. Choosing the route of hysterectomy for benign disease. ACOG Committee Opinion No. 701. American College of Obstetricians and Gynecologists. *Obstet Gynecol* 2017; 129:e155–9.
41. Zaritsky E, Tucker LY, Neugebauer R, Chou T, Flanagan T, Walter AJ, et al. Minimally invasive hysterectomy and power morcellation trends in a west coast integrated health system. *Obstet Gynecol* 2017;129:996–1005.
42. Tusheva OA, Cohen SL, Einarsson JI. Hand-assisted approach to laparoscopic myomectomy and hysterectomy. *J Minim Invasive Gynecol* 2013;20:234–7.
43. Miller CE. Morcellation equipment: past, present, and future. *Curr Opin Obstet Gynecol* 2018;30:69–74.
44. Cohen SL, Morris SN, Brown DN, Greenberg JA, Walsh BW, Gargiulo AR, et al. Contained tissue extraction using power morcellation: prospective evaluation of leakage parameters. *Am J Obstet Gynecol* 2016;214:257.e1–6.
45. Hong MK, Wei YC, Chu TY, Wang JH, Ding DC. Safety and efficacy of contained manual morcellation during laparoscopic or robotic gynecological surgery. *Int J Gynaecol Obstet* 2020;148:168–73.
46. Lambat Emery S, Pluchino N, Petignat P, Tille JC, Pache JC, Pinto J, et al. Cell spillage after contained electromechanical morcellation using a specially designed in-bag system for laparoscopic myomectomy: prospective cohort pilot study. *J Minim Invasive Gynecol* 2019;26:1351–6.
47. Cohen SL, Hariton E, Afshar Y, Siedhoff MT. Updates in uterine fibroid tissue extraction. *Curr Opin Obstet Gynecol* 2016;28:277–82.
48. Winner B, Porter A, Velloze S, Biest S. Uncontained compared with contained power morcellation in total laparoscopic hysterectomy. *Obstet Gynecol* 2015;126:834–8.
49. Gil-Gimeno A, Laberge PY, Lemyre M, Gorak E, Maheux-Lacroix S. Morcellation during total laparoscopic hysterectomies: implications of the use of a contained bag system. *J Obstet Gynaecol Can* 2020;42:839–45.
50. Vargas MV, Cohen SL, Fuchs-Weizman N, Wang KC, Manoucheri E, Vitonis AF, et al. Open power morcellation versus contained power morcellation within an insufflated isolation bag: comparison of perioperative outcomes. *J Minim Invasive Gynecol* 2015;22:433–8.
51. Clarke-Pearson DL, Geller EJ. Complications of hysterectomy. *Obstet Gynecol* 2013;121:654–73.
52. Wiser A, Holcroft CA, Tulandi T, Abenham HA. Abdominal versus laparoscopic hysterectomies for benign diseases: evaluation of morbidity and mortality among 465,798 cases. *Gynecol Surg* 2013;10:117–22.
53. Aarts JW, Nieboer TE, Johnson N, Tavender E, Garry R, Mol BW, Kluivers KB. Surgical approach to hysterectomy for benign gynaecological disease. *Cochrane Database of Systematic Reviews* 2015, Issue 8. Art. No.: CD003677.

54. Bhavé Chittawar P, Franik S, Pouwer AW, Farquhar C. Minimally invasive surgical techniques versus open myomectomy for uterine fibroids. *Cochrane Database of Systematic Reviews* 2014, Issue 10. Art. No.: CD004638.
55. Wright JD, Cui RR, Wang A, Chen L, Tergas AI, Burke WM, et al. Economic and survival implications of use of electric power morcellation for hysterectomy for presumed benign gynecologic disease. *J Natl Cancer Inst* 2015;107:djv251.
56. Hur HC, King LP, Klebanoff MJ, Hur C, Ricciotti HA. Fibroid morcellation: a shared clinical decision tool for mode of hysterectomy. *Eur J Obstet Gynecol Reprod Biol* 2015;195:122–7.
57. Siedhoff MT, Wheeler SB, Rutstein SE, Geller EJ, Doll KM, Wu JM, et al. Laparoscopic hysterectomy with morcellation vs abdominal hysterectomy for presumed fibroid tumors in premenopausal women: a decision analysis. *Am J Obstet Gynecol* 2015;212:591.e1–8.
58. Siedhoff MT, Doll KM, Clarke-Pearson DL, Rutstein SE. Laparoscopic hysterectomy with morcellation vs abdominal hysterectomy for presumed fibroids: an updated decision analysis following the 2014 Food and Drug Administration safety communications. *Am J Obstet Gynecol* 2017;216:259.e1–6.
59. Picerno TM, Wasson MN, Gonzalez Rios AR, Zuber MJ, Taylor NP, Hoffman MK, et al. Morcellation and the incidence of occult uterine malignancy: a dual-institution review. *Int J Gynecol Cancer* 2016;26:149–55.
60. Ouldamer L, Rossard L, Arbion F, Marret H, Body G. Risk of incidental finding of endometrial cancer at the time of hysterectomy for benign condition. *J Minim Invasive Gynecol* 2014;21:131–5.
61. Von Barga EC, Grimes CL, Mishra K, Wang R, Haviland MJ, Hacker MR, et al. Prevalence of occult pre-malignant or malignant pathology at the time of uterine morcellation for benign disease. *Int J Gynaecol Obstet* 2017;137:123–8.
62. Tulandi T, Leung A, Jan N. Nonmalignant sequelae of unconfined morcellation at laparoscopic hysterectomy or myomectomy. *J Minim Invasive Gynecol* 2016;23:331–7.
63. Informed consent. ACOG Committee Opinion No. 439. American College of Obstetricians and Gynecologists. *Obstet Gynecol* 2009;114:401–8.

---

Published online on February 18, 2021.

Copyright 2021 by the American College of Obstetricians and Gynecologists. All rights reserved. No part of this publication may be reproduced, stored in a retrieval system, posted on the internet, or transmitted, in any form or by any means, electronic, mechanical, photocopying, recording, or otherwise, without prior written permission from the publisher.

**American College of Obstetricians and Gynecologists**  
**409 12th Street SW, Washington, DC 20024-2188**

Uterine morcellation for presumed leiomyomas. ACOG Committee Opinion No. 822. American College of Obstetricians and Gynecologists. *Obstet Gynecol* 2021;137:e63–74.

---

*This information is designed as an educational resource to aid clinicians in providing obstetric and gynecologic care, and use of this information is voluntary. This information should not be considered as inclusive of all proper treatments or methods of care or as a statement of the standard of care. It is not intended to substitute for the independent professional judgment of the treating clinician. Variations in practice may be warranted when, in the reasonable judgment of the treating clinician, such course of action is indicated by the condition of the patient, limitations of available resources, or advances in knowledge or technology. The American College of Obstetricians and Gynecologists reviews its publications regularly; however, its publications may not reflect the most recent evidence. Any updates to this document can be found on [acog.org](http://acog.org) or by calling the ACOG Resource Center.*

*While ACOG makes every effort to present accurate and reliable information, this publication is provided "as is" without any warranty of accuracy, reliability, or otherwise, either express or implied. ACOG does not guarantee, warrant, or endorse the products or services of any firm, organization, or person. Neither ACOG nor its officers, directors, members, employees, or agents will be liable for any loss, damage, or claim with respect to any liabilities, including direct, special, indirect, or consequential damages, incurred in connection with this publication or reliance on the information presented.*

*All ACOG committee members and authors have submitted a conflict of interest disclosure statement related to this published product. Any potential conflicts have been considered and managed in accordance with ACOG's Conflict of Interest Disclosure Policy. The ACOG policies can be found on [acog.org](http://acog.org). For products jointly developed with other organizations, conflict of interest disclosures by representatives of the other organizations are addressed by those organizations. The American College of Obstetricians and Gynecologists has neither solicited nor accepted any commercial involvement in the development of the content of this published product.*